

CASE REPORT

Open Access

Kocuria varians infection associated with brain abscess: A case report

Cheng-Yu Tsai¹, Shou-hsin Su², Yu-Hsin Cheng³, Yu-lin Chou¹, Tai-Hsin Tsai¹ and Ann-Shung Lieu^{*1}

Abstract

Background: *Kocuria*, established by Stackebrandt et al., previously was classified into *Micrococcus*. Only two species, *K. rosea* and *K. kristinae* are reported to be associated as pathogenic and found with catheter-related bacteremia and acute cholecystitis.

Case presentation: We herein report the first case of brain abscess caused by *Kocuria varians*, a gram-positive microorganism, in a 52-year-old man. Hematogenous spread is the probable pathogenesis.

Conclusions: This report presents a case of *Kocuria varians* brain abscess successfully treated with surgical excision combined with antimicrobial therapy. In addition, Vitek 2 system has been used to identify and differentiate between coagulase-negative staphylococcus.

Background

Kocuria spp. are gram-positive, strictly aerobic microorganisms. Previously they were classified into genus *Micrococcus*, but have now been removed from *Micrococcus* based on phylogenetic and chemotaxonomic analysis [1]. This bacterial cluster consists of nine species and is generally considered to be non-pathogenic commensals that colonize the skin, mucosa and oropharynx. However, they can be opportunistic pathogens in immunocompromised patients, though documented cases of infections are rare. We describe a case which presented as a brain abscess caused by *Kocuria varians*. To our knowledge, this is the first reported case of *Kocuria varians* associated with brain abscess in the English literature.

Case presentation

A 52-year-old male, who had a history of diabetes mellitus and hypertension without regular medication control, presented without fever, but with headache and dizziness for 2 months. These headaches were located over the right occipital area without radiation. The headache worsened while thinking or looking at objects for a long time. Also, he did not have any cutaneous/mucosal lesions prior to or during the period in which these head-

aches occurred and he had not received any injections or acupuncture. On hospital admission, he still did not have any fever and physical examination revealed normal findings, but a neurological examination showed left side homonymous hemianopia. Brain computerized tomography (CT) (Fig. 1A) and magnetic resonance (MR) (Fig. 1B) showed a right occipital brain abscess. Systemic third-generation cephalosporins (Ceftazidime) and Metronidazole were initially administered pre-operatively for one day by IV. Then, craniotomy and surgical extirpation were performed promptly after a completed image study identified the abscess. The capsule of the abscess was completely removed during the operation. Pus culture yielded a gram-positive microorganism identified as *Kocuria Varians* by the Vitek 2 system. Post-operatively, Metronidazole was ceased due to the outcome of an antibiotic susceptibility test report, for 4 weeks Ceftazidime was administered and then shifted to oral form third-generation cephalosporins (Ceftibuten) for 2 weeks. Neurological function was successfully recovered after operation

Microbiological diagnosis

Culture of brain abscess was performed with sheep blood agar, eosin methylene blue agar and chocolate agar. The plates were incubated at 35 degrees for 48 hours. Anaerobic culture was performed on Bacteroides Bile Esculin agar and incubated at 35 degrees for 48 hours. Gram-pos-

* Correspondence: teishin8@hotmail.com

¹ Division of Neurosurgery, Department of Surgery, Kaohsiung Medical University Hospital, Kaohsiung, Taiwan

Full list of author information is available at the end of the article

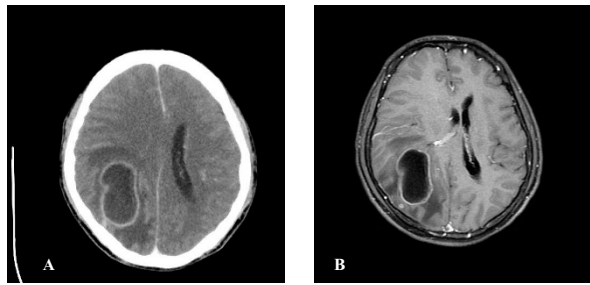


Figure 1 A. Axial brain CT after contrast medium injection showing a ring-enhancement lesion with perifocal edema over right occipital area. **B.** Axial T1-weighted MR image of the brain after gadolinium injection revealed ring-enhancing cystic lesion with mass effect suggestive of right occipital abscess

itive cocci arranged in tetrads and non-hemolytic, catalase positive, coagulase negative and nonmotile were found. (Fig 2). Anaerobic culture did not find any anaerobic microorganism activity. Identification was performed using the Biome Rieux Vitek 2 system. The isolate was

identified as *Kocuria varians* with very good validity (Fig 3). A useful alternative means of identification, 16s RNA was not performed. The antibiotics sensitivity was performed and sensitive to penicillin, cloxacillin, cefmetazole, clindamycin, Meropenem, penicillin G, Ampicillin/sulbactam, Piperacillin/tazobactam.

Discussion

The incidence of brain abscess varies between 1500 to 2500 cases/year in the US, with higher incidences in developing countries [2]. It occurs with the following predisposing sources: 1) contiguous spread; 2) hematogenous spread; 3) head trauma; and 4) neurosurgical procedure. According to the previous literature, the most common modes of direct contiguous spread were from the middle ear, mastoid infections and paranasal sinus [3]. But nowadays, hematogenous spread has become the most common source [2]. The organisms that cause brain abscess are typically bacterial in origin. *Streptococcus* and *staphylococcus* are the most frequent organisms and can

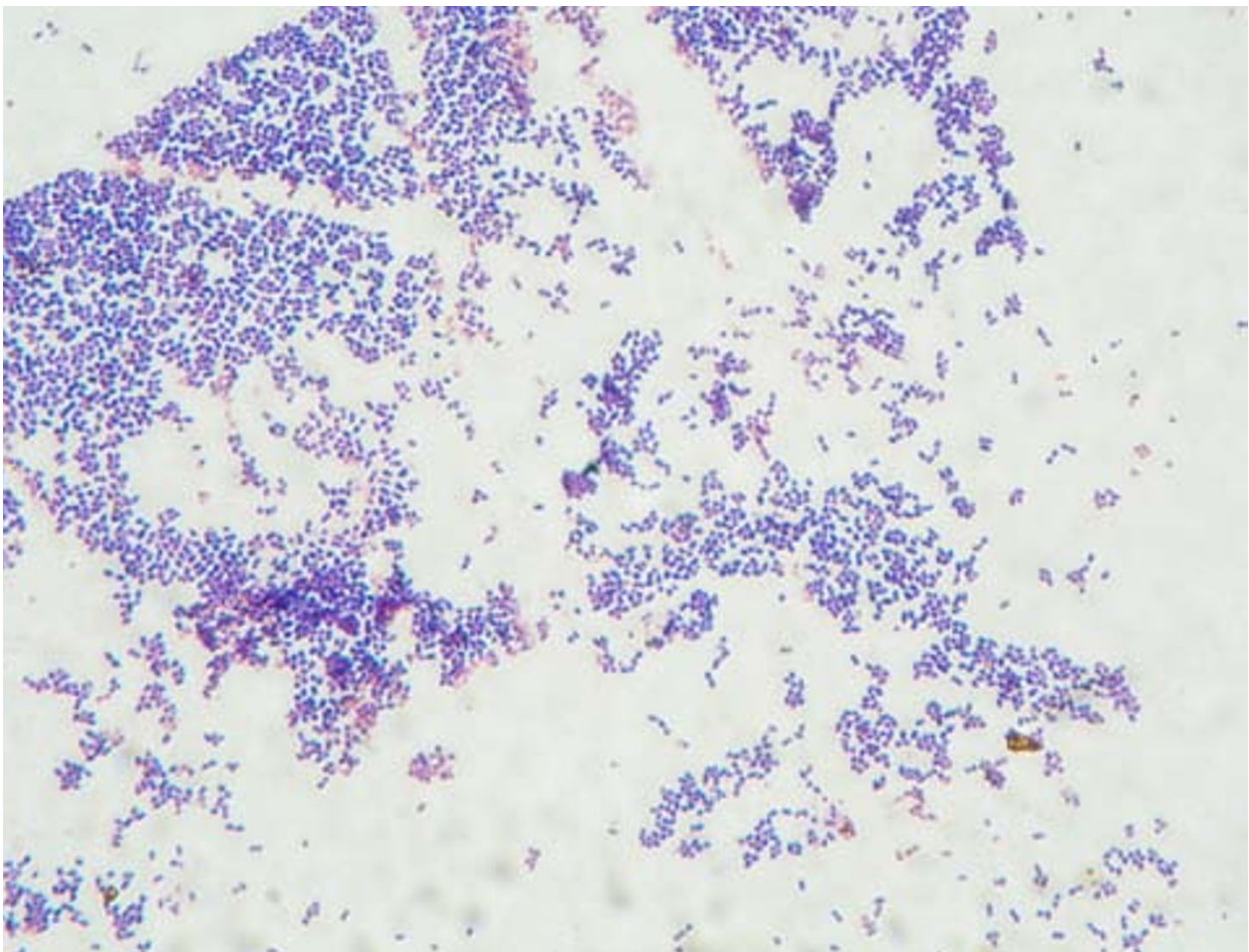


Figure 2 Gram stain revealed gram-positive cocci arranged intetrads

```

Date: 03/25/2009 10:22:07          bioMerieux          Page: 1
WSVT2-R05.01                      Vitek 2 Lab Report

Accession ID: 0903101785-1
LSN configured for demoless operation.
Position: (00000EEA9490) Serial No. 3037 SCS-01 Mar 23 10:36:45
Type: Gram Positive Identification
Status: TRANS (05.75)
Organism: Kocuria varians
Origin: GP Identification

AMY - PIPLC - dXYL - ADH1 + BGAL - AGLU -
APPA ? CDEX - AspA - BGAR - AMAN - PHOS ?
LeuA - ProA - BGURr - AGAL - PyrA - BGUR -
AlaA + TyrA - dSOR - URE + POLYB - dGAL -
dRIB - lLATk - LAC - NAG - dMAL - BACI -
NOVO - NC6.5 - dMAN - dMNE - MBdG - PUL -
dRAF - O129R - SAL - SAC - dTRE - ADH2s +
OPTO +

Confidence Level: Very Good Identification

Probability Organism
93.00 Kocuria varians

- Tests contraindicating typical biopattern -
Kocuria varians
ADH2s (0.01) OPTO (0.04)

LOT 242121340 EXP DATE 10-Apr-2010 ( 2421 2134 0133 7163 )
[ iwfn awfn dilP inc05:48:42 ver0244 ]
    
```

Figure 3 Vitek 2 lab reported organism is *kocuria varians*

be isolated from abscesses of all types and at all sites, whereas *Enterobacteriaceae* and *Bacteroides spp.* are isolated from otogenic temporal lobe abscess [4]. In neonates, *Proteus* and *Citrobacter spp.* are the most common organisms. Occasionally *Mycobacterium tuberculosis* as well as fungal infections can act as organisms. *Listeria monocytogenes* and *Burkholderia pseudomallei* are rarely reported [4]. *Micrococcus spp.* associated with brain abscess is mentioned in only two case reports in the English literature [5,8]. In reviewing the English literatures, *Kocuria varians* related to brain abscess has not yet been documented. Our case is the first reported case in which brain abscess is caused by *Kocuria varians*.

Kocuria spp. are gram-positive, aerobic microorganisms and found as normal skin flora in humans and other mammals. Infections related to *Kocuria spp.* are uncommon but can be opportunistic pathogens in immunocompromised patients with underlying diseases. *Kocuria spp.* was previous classified as *Micrococcus spp.* Recently, Stackebrandt and colleagues made a taxonomic revision of *Micrococcus spp.* and reclassified it in the new genus *Kocuria spp.* (*Kocuria rosea*; *K. kristinae*; *K. varians*; *K. palustris*; and *K. rhizophila ap. Nov.*) [2,6]. The organism *Micrococcus luteus* has been reported as a pathogen in meningitis [7], intracranial abscess [8], arthritis [9], pneumonia [10] catheter-related sepsis in patients with hemo-

dialysis [11], or leukemia treatment [12]. *K. rosea* and *K. kristinae* have been reported as pathogens causing catheter-related bacteremia and acute cholecystitis [13-15]. Due to the normal flora of skin or oropharynx and the reported catheter-related bacteremia of other species, the possible predisposing source of *Kocuria varians* is by hematogenous spread to brain parenchyma.

Due to phenotypic variability, misidentification of coagulase-negative staphylococcus as *Kocuria* by using standard biochemical analysis is common [16]. Therefore the Vitek 2 system has been used, which is scored as being "very good identification" and is reportedly used in both morphotypes [17]. Also the utilization of genotypic assay, such as 16s RNA is used to confirm species identity [15].

Most strains of *Kocuria* and *Micrococcus* were reported to be sensitive to doxycycline, ceftriaxone, cefuroxime, amikacin, and amoxicillin and erythromycin [18], but in consideration of BBB and penetration of the abscess capsule, third-generation cephalosporins should be used. In our case, surgical excision was performed and then third-generation cephalosporins were administered intravenously for 4 weeks and then shifted to oral form third-generation cephalosporins for 2 weeks as an adequate therapy.

Conclusion

Herein we report the first case of *Kocuria varians* associated with brain abscess in the reviewing the English literature. Because *Kocuria spp.* is found as normal flora and the hematogenous spread of other related species in reported cases, we supposed *Kocuria varians* caused brain abscess by hematogenous spreading. Besides Vitek 2 system, 16s RNA may be additionally used to confirm and thus avoid misidentification as coagulase-negative staphylococcus. Surgical excision combined with third-generation cephalosporins could serve as an excellent standard therapy for *Kocuria varians* brain abscess.

Competing interests

The authors declare that they have no competing interests.

Authors' contributions

CT, AL, YC and TT carried out the clinical study of the patient. SS carried out the culture and specific identification of the bacterium. CT drafted the manuscript. All authors read and approved the final manuscript.

Acknowledgements

Written consent was obtained from the patient for publication of this case report.

Author Details

¹Division of Neurosurgery, Department of Surgery, Kaohsiung Medical University Hospital, Kaohsiung, Taiwan, ²Department of Internal Medicine, Kaohsiung Municipal United Hospital, Kaohsiung, Taiwan and ³Department of Nursing, Kaohsiung Medical University Hospital, Kaohsiung, Taiwan

Received: 28 November 2009 Accepted: 27 April 2010

Published: 27 April 2010

References

1. Stackebrandt E, Koch C, Gvozdiak O, Schumann P: **Taxonomic dissection of the genus *Micrococcus*: *Kocuria* gen. nov., *Nesterenkonia* gen. nov., *Kytococcus* gen. nov., *Dermacoccus* gen. nov., and *Micrococcus Cohn 1872* gen. emend.** *Int J Syst Bacteriol* 1995, **45**:682-692.
2. Greenberg MS: **Handbook of Neurosurgery.** 5th edition. New York: Thieme; 2001:217-223.
3. Jennett B, Miller JD: **Infection after depressed fracture of skull implications for management of nonmissile injuries.** *J Neurosurg* 1972, **36**:333-339.
4. Moorthy RK, Rajshekhar V: **Management of brain abscess: an overview.** *Neurosurg Focus* 2008, **24**(6):E3.
5. Marchiori C, Tonon E: **Brain abscesses after extracranial infections of the head and neck area.** *HNO* 2003, **51**(10):813-22.
6. Märialigeti K: ***Kocuria palustris* sp. nov. and *Kocuria rhizophila* sp. nov., isolated from the rhizoplane of the narrow-leaved cattail (*Typha angustifolia*).** *Int J Syst Bacteriol* 1999, **49**:167-173.
7. Fosse T, Peloux Y, Granthil C, Toga B, Bertrando J, Sethian M: **Meningitis due to *Micrococcus luteus*.** *Infection* 1985, **13**:280-281.
8. Selladurai B, Sivakumaran S, Subramanian A, Mohamad AR: **Intracranial suppuration caused by *Micrococcus luteus*.** *Br J Neurosurg* 1993, **7**:205-208.
9. Wharton M, Rice JR, McCallum R, Gallis HA: **Septic arthritis due to *Micrococcus luteus*.** *J Rheumatol* 1986, **13**:659-660.
10. Souhami L, Feld R, TuVnell PG, Fellner T: ***Micrococcus luteus* pneumonia: a case report and review of the literature.** *Med Pediatr Oncol* 1979, **7**:309-314.
11. Peces R, Gago E, Tejada F, Laures AS, Alvarez-Grande J: **Relapsing bacteraemia due to *Micrococcus luteus* in a haemodialysis patient with Perm-Cath catheter.** *Nephrol Dial Transplant* 1997, **12**:2428-2429.
12. Shanks D, Goldwater P, Pena A, Saxon B: **Fatal *Micrococcus* sp. Infection in a child with leukaemia - a cautionary case.** *Med Pediatr Oncol* 2001, **37**:553-554.
13. Altuntas F, Yildiz O, Eser B, Gundogan K, Sumerkan B, Cetin M: **Catheter-related bacteremia due to *Kocuria rosea* in a patient undergoing peripheral blood stem cell transplantation.** *BMC Infect Dis* 2004, **4**:62.
14. Basaglia G, Carretto E, Barbarini D, Moras L, Scalone S, Marone P, De Paoli P: **Catheter-related bacteremia due to *Kocuria kristinae* in a patient with ovarian cancer.** *J Clin Microbiol* 2002, **40**:311-313.
15. Edmond Ma SK, Chris Wong LP, Kristi Lai TW, Edmond Chan CH, Yam WC, Angus Chan CW: ***Kocuria kristinae* infection associated with acute cholecystitis.** *BMC Infect Dis* 2005, **5**:60.
16. Ben-Ami R, Navon-Venezia S, Schwartz D, Schlezinger Y, Mekuzas Y, Carmeli Y: **Erroneous reporting of coagulase-negative staphylococci as *Kocuria* spp. by the Vitek 2 system.** *J Clin Microbiol* 2005, **43**:1448-1450.
17. Ben-Ami R, Navon-Venezia S, Schwartz D, Carmeli Y: **Infection of a Ventriculoatrial Shunt with Phenotypically Variable *Staphylococcus epidermidis* Masquerading as Polymicrobial Bacteremia Due to Various Coagulase- Negative Staphylococci and *Kocuria varians*.** *J Clin Microbiol* 2003, **41**:2444-2447.
18. Szczerba I: **Susceptibility to antibiotics of bacteria from genera *Micrococcus*, *Kocuria*, *Nesterenkonia*, *Kytococcus* and *Dermacoccus*.** *Med Dosw Mikrobiol* 2003, **55**:75-80.

Pre-publication history

The pre-publication history for this paper can be accessed here:
<http://www.biomedcentral.com/1471-2334/10/102/prepub>

doi: 10.1186/1471-2334-10-102

Cite this article as: Tsai et al., *Kocuria varians* infection associated with brain abscess: A case report *BMC Infectious Diseases* 2010, **10**:102

Submit your next manuscript to BioMed Central and take full advantage of:

- Convenient online submission
- Thorough peer review
- No space constraints or color figure charges
- Immediate publication on acceptance
- Inclusion in PubMed, CAS, Scopus and Google Scholar
- Research which is freely available for redistribution

Submit your manuscript at
www.biomedcentral.com/submit

